



A Review on Diabetic Retinopathy Detection

J D Labhade¹, Prof. L K Chouthmol²

^{1,2} E&TC (Signal Processing) Department, SKH Late G N Sapkal COE, Anjaneri, Nasik

Abstract-- A great challenge in the biomedical engineering is the non-invasive assessment of the physiological changes occurring inside the human body. Specifically, detecting the abnormalities in the human eye is extremely difficult due to the various complexities associated with the process. Retina is the significant part of the human eye which can reflect the abnormal changes in the human eye. Hence, retinal images captured by digital cameras can be used to identify the nature of the abnormalities affecting the human eye. Retinal image analysis has gained sufficient importance in the research arena due to the necessity for disease identification techniques. Abnormality detection using these techniques is highly complex since these diseases affect the human eye gradually. Conventional disease identification techniques from retinal images are mostly dependent on manual intervention. Since human observation is highly prone to error, the success rate of these techniques is quite low. Since treatment planning varies for different abnormalities, the accuracy of the identification techniques must be significantly high. Lack of accuracy in these techniques may lead to fatal results due to wrong treatment. Hence, there is a significant necessity for automation techniques with high accuracy for retinal disease identification applications. Several automation techniques have been reported in the literature for retinal image analysis.

Keywords- Microaneurysms, hemorrhage, hard exudates, soft exudates, sensitivity, specificity, accuracy.

1. INTRODUCTION

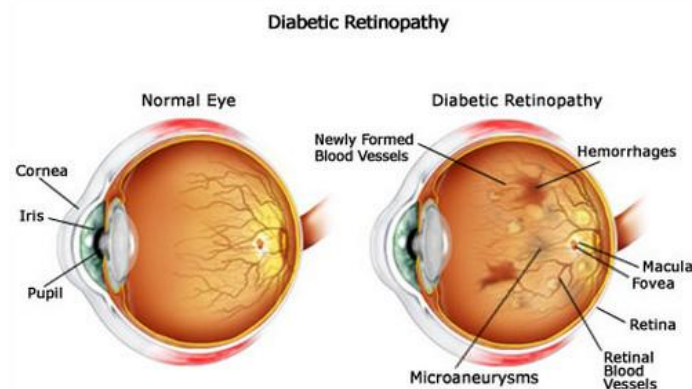


Figure 1. Normal Eye and Diabetic retionopathic eye

Diabetic retinopathy occurs in patients suffering from diabetes, which causes damage to the retina of the eye. This eventually leads to total vision loss. Diabetes is caused due to the body's inability to store and make use of the sugar level in the blood. Usually there are no early visible symptoms of the disease and as the disease progresses the presence of microaneurysms, exudates both hard and soft and new blood vessels can be observed. The main anatomical features in the image, notably the optic disc and the macula. The optic disc is a circular shaped anatomical structure with a bright appearance. The fovea is the very center of the macula, the site of our sharpest vision. The diabetes may cause abnormalities in the retina (diabetic retinopathy), kidneys (diabetic nephropathy), and nervous system (diabetic neuropathy). The diabetes is also a major risk factor in

cardiovascular diseases. The diabetic retinopathy typically begins as small changes in the retinal capillaries. [1]

Diabetic retinopathy causes damage to the blood vessels in the retina, and this causes fluid to leak into the macula region of the retina causing it to swell and leading to blurred vision. In order to improve blood circulation blood vessels form on the surface and these abnormal vessels leak and block vision. Diabetic retinopathy is of two types namely non proliferative and proliferative type. Non proliferative is the early stage of the disease characterised by the presence of micro aneurysms. As the disease progresses the retina is deprived of oxygen and new blood vessels are formed in the retina. These vessels eventually leak and leads to clouding vision. The first detectable abnormalities are microaneurysms (Ma) which are local distensions of the retinal capillary and which cause intraretinal hemorrhage (H) when ruptured. [2]

Microaneurysms are small red dots on the retinal surface, which occur due to capillary occlusion leading to lack of oxygen and progression of the disease. They are less than the diameter of the optic vein. Accumulation of proteins and lipids occur in the form of exudates. Vision loss occurs when they occur in the macula. Exudates appear as yellow or white structures in the retina. There are two types of exudates based on their appearance and occurrence. Hard exudates have well defined boundaries and the soft exudates have unclear boundaries also know as cotton wool spots. Haemorrhages in the retina occur due to bleeding. Dot haemorrhages lie deep within the retina and reflect leakage of the veins and capillaries. Dot haemorrhages are an indication of diabetic retinopathy.

A novel method of Gaussian Intensity feature input to VQ classifier, to diagnose diabetic retinopathy, using the technique of Vector Quantization. Two sets of images have been taken in our approach, of which one is training set and the other set is used for testing. The major features are extracted in training process and a features set is formed. This training set is used to extract and recognize the features in the testing set that have the same features as in the training vector. The features specific to this disease were used in making the codebook and with this codebook performed the features matching and analysis of the images using the vector. The size of the codebook depends on the number of feature points in the image and also on the number of segments dividing the fundus images. The results obtained were satisfactory as the method detected the pathology with quite good percentage accuracy of 91.04%. [3]

Image preprocessing, morphological processing techniques and texture analysis methods were applied on the fundus images to detect the features such as area of blood vessels, hard exudates and the contrast, homogeneity. The features were then fed to the support vector machine (SVM). They demonstrated a classification accuracy of 93%, sensitivity of 90% and specificity of 100%. [4]

The author mainly contributed the reduction in the number of features used for lesion classification by feature ranking using Adaboost where 30 top features were selected out of 78. A novel two-step hierarchical classification approach was proposed where the nonlesions or false positives were rejected in the first step. In the second step, the bright lesions were classified as hard exudates and cotton wool spots, and the red lesions were classified as hemorrhages and microaneurysms. This lesion classification problem deals with unbalanced datasets and SVM or combination classifiers derived from SVM using the Dempster–Shafer theory were found to incur more classification error than the GMM and kNN classifiers due to the data imbalance. [5]

The paper proposes a classification system of NPDR based on exudate features. The main processes in this are exudate segmentation, feature extraction and the classification of NPDR severity level. The exudate segmentation performs the exudate extraction and transforms the segmented exudates into a binary image. Then, the four features (area, perimeter, energy and standard deviation) of each exudate image are extracted in the feature extraction process. The extracted features are trained and tested using soft margin SVM as a classification model. The experimental result shows that soft margin SVM model achieves high accuracy (90.54 %) when classify retinal fundus images as moderate NPDR or severe NPDR. [6]

They proposed a system to (i) detect blood vessel, (ii) identify hemorrhages and (iii) classify different stages of diabetic retinopathy into normal, moderate and nonproliferative diabetic retinopathy (NPDR). Retinal vascular were segmented utilising the contrast between the blood vessels and surrounding background. Hemorrhage candidates were detected using density analysis and bounding box techniques. Finally, classification of the different stages of eye disease was done using Random Forests technique based on the area and perimeter of the blood vessels and hemorrhages. Accuracy assessment of the classified output revealed that normal cases were classified with 90% accuracy while moderate and severe NPDR cases were 87.5% accurate. [7]

CONCLUSION

This paper presents a review on diabetic retinopathy techniques. In the terms of sensitivity, specificity and positive prediction accuracy considering three cases during classification (normal, moderate and severe) compared to the four cases namely, normal, moderate NPDR, severe NPDR and proliferative NPDR, every method had its own advantage and disadvantage. However, the scope and direction for further work are to include more instances of retinal images to construct a robust classifier for detecting different stages of diabetic retinopathy (i.e. for training and testing) to achieve higher accuracy. The efficiency of the correct classification can also be improved by extracting more number of features from the images.

REFERENCES

- I. Laszlo Kovacs, Rashid Jalal Qureshi, Brigitta Nagy, Balazs Harangi, Andras Hajdu "Graph Based Detection of Optic Disc and Fovea in Retinal Images", 4 th International Workshop on Soft Computing, IEEE, 2010.
- II. T. Kauppi, V. Kalesnykiene, J.K. Kamarainen, L. Lensu, I. Sorri, A. Raninen, R. Voutilainen, J. Pietil, H. Kiviinen, H. Uusitalo "DIARETDB1 diabetic retinopathy database and evaluation protocol", In Proc. of the Medical Image Understanding and Analysis, Aberystwyth, UK, pp. 6165, 2007.
- III. Divyanjali Satyarthi, B.A.N. Raju, and S. Dandapat "Detection of Diabetic Retinopathy in Fundus Images using Vector Quantization Technique" India Conference, 2006 Annual IEEE, pp. 1 – 4, Sept. 2006.
- IV. DU Ning, LI Yafen "Automated Identification of Diabetic Retinopathy Stages Using Support Vector Machine" Control Conference (CCC), 2013 32nd Chinese, pp. 3882 – 3886, 26-28 July 2013.
- V. Sohini Roychowdhury, Dara D. Koozekanani, and Keshab K. Parhi "DREAM: Diabetic Retinopathy Analysis Using Machine Learning" IEEE JOURNAL OF BIOMEDICAL AND HEALTH INFORMATICS, VOL. 18, NO. 5, SEPTEMBER 2014.
- VI. Handayani Tjandrasa, Ricky Eka Putra, Arya Yudhi Wijaya, Isye Arieshanti "Classification of Non-Proliferative Diabetic Retinopathy Based on Hard Exudates Using Soft Margin SVM" 2013 IEEE International Conference on Control System, Computing and Engineering, pp. 376- 380, 29 Nov. - 1 Dec. 2013.
- VII. Kanika Verma, Prakash Deep and A. G. Ramakrishnan "Detection and Classification of Diabetic Retinopathy using Retinal Images" India Conference (INDICON), 2011 Annual IEEE, pp. 1 – 6, 16-18 Dec. 2011.