

Detection And Classification of Uterine Fibroid Using Ultrasound Images

1. Dr. C. Seldev Christopher¹, T. Vajith Malar²

1. Professor/ECE,

St.Xavier's Catholic College of Engineering, Chunkankadai

2. Final Year M.E/Medical Electronics,

St.Xavier's Catholic College of Engineering,

Abstract - Ultrasound imaging technique is the most effective tool used for detecting fibroids present in uterus. Mostly women's are affected from the ovarian cyst and uterine fibroid diseases after their age 50. Generally fibroid affects the uterus. By the use of this Ultrasound imaging technique we easily found the size and type of fibroids. It is an initial method, because 90% of fibroids size was easily found and here no harmful radiation will be produced from the device. In the existing method histogram equalization are used in the preprocessing step. Then gray thresholding is applied to convert the image into the binary one. Then active contour-based image segmentation is done. After that Then active contour-based image segmentation and HOG feature extraction. Pre-processing is done for adjusting image intensities. In this project Histogram Equalization technique is used to adjust the intensity of image. By using active contour image segmentation, the contour energy is minimized and specifies the curve on the image that moves to find the object boundaries. The mask argument specifies the initial state of the contour. HOG (Histogram Oriented Gradient) feature extraction is performed on individual objects to compute HOG on each cell. After feature extraction the images are classified using Artificial Neural Network.

Index Terms – Ultrasound, fibroid, Uterine Fibroid, HOG (Histogram Oriented Gradient).

I. INTRODUCTION

Mostly women's after their age 50, they are affected more by uterus diseases. The different modes of imaging are Ultrasonic, MRI, CT. Ultrasonic imaging is an initial method. In which 90% of cyst and fibroid will be found. It is efficient method to view the abdominal area. This technique uses the ultrasound waves. It does not produce any harmful radiation. This method is inexpensive one. The normal uterus size is, 7.5cm(3 inch) length, 4.5cm(2 inch)width, and weight is 60-200gm. The shape of the uterus

(womb) is a pear-shaped organ. The structure of uterus and ovary is given by,

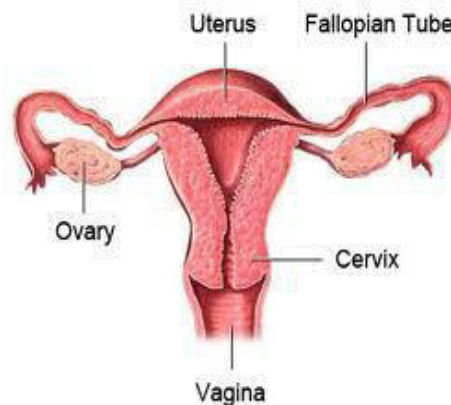


FIGURE: 1.1 NORMAL UTERUS

1.1 UTERINE FIBROIDS

Uterine fibroids also referred as leiomyomas are the most common tumors persist within the wall of the female genital tract. Uterine fibroids are mostly benign. That is non-cancerous. Fibroids are tumors of the smooth muscle found in the wall of the uterus. They can develop within the uterine wall itself or attach to it. They may grow as a single tumor or in clusters. This abnormality is predominant among woman of childbearing age where the secretion of estrogen hormone is significant. The most crucial factor is that the presence of fibroid can cause infertility and repeated miscarriage.

Fibroids have been reported to occur in up to 70% of women by the age of 50 years and are especially common in black women, who also often have more severe disease. These benign tumors are hormone dependent, responding to both estrogen and progesterone; they often increase in size during pregnancy and usually decrease in size after menopause. Early age at menarche and obesity are risk factors for the development of fibroids, likely due to the increased exposure to estrogen.

Uterine fibroids may occur singly but most often are multiple and vary in size from an unnoticeable few millimeters to over 20

cm in diameter, significantly enlarging the abdominal cavity. They are named according to their location. Symptoms and treatment options are affected by the size, number, and location of the leiomyomas. Despite extensive research on the factors involved in the growth of leiomyomas, the precise causes of these tumors still remain unknown. Several predisposing factors have been identified, including age (late reproductive years), obesity, and African-American ethnicity. These tumors contain estrogen and progesterone receptors, and, typically develop in women at fertile age, increase with age, and shrink after the menopause. The growth of leiomyomas is ovarian hormones dependent.

1.1.1 TYPES OF UTERINE FIBROIDS

Uterine fibroids are classified based on their locations formed in the uterus. The different types of uterine fibroid are,
 Subserosal
 Intramural
 Submucosal
 Pedunculated
 Cervical

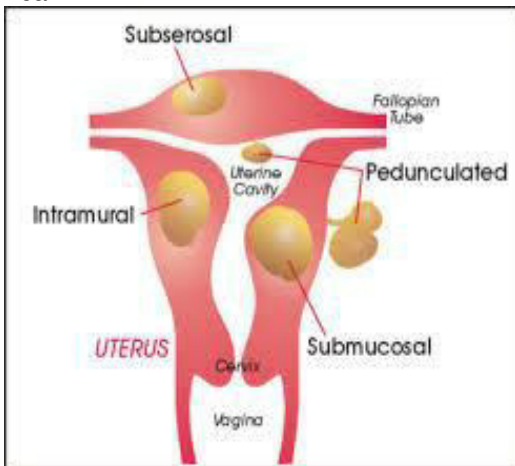


FIGURE 1.2 TYPES OF FIBROIDS IN UTERUS SUBSEROSAL FIBROIDS

It develops on the outer uterine wall. This type of fibroid tumor can continue to grow outer ward increasing in size. This growth will put additional pressure on the surrounding organs. Symptoms are abdomen pain, pelvic pain and pressure. Depending on the severity and the location of the fibroids other complications can accompany this pain and pressure.

INTRAMURAL FIBROIDS

It develops within the uterine wall and expands from there. When a tumor size increases, it tends to make the uterus size

larger than normal. Symptoms are excessive menstrual bleeding, pelvic pain. Depends upon the growth of fibroids, the additional pressure will be given to the surrounding organs. Which cause frequent urination.

SUBMUCOSAL FIBROIDS

It develops just under the lining of the uterine cavity. The tumor size increases, then the size of the uterus cavity also increases. And it blocks the fallopian tubes. It causes complication with fertility. Some fibroid tumors don't produce any symptoms at all, while other can be severely symptomatic. The symptoms are very heavy excessive bleeding and prolonged menstruation. These untreated, prolonged or excessive bleeding can cause more complicated problems, such as anemia and/or fatigue.

PEDUNCULATED FIBROIDS

It grows on stalk, resulting in pedunculated, submucosal (or) subserosal fibroids. These fibroids can grow into the uterus & also can grow on the outside of the uterine wall. Symptoms are severe pain and pressure. Symptoms associated with pedunculated fibroid tumors include pain and pressure as the fibroids can sometimes twist on the stalk. This type of fibroid causes frequent urination.

CERVICAL FIBROIDS

It grows in the wall of the cervix (neck of the womb). Very difficult to remove these fibroids without damaging the surrounding areas. These fibroids also grow inside and outside of the uterine wall. It causes severe pain and pressure. Also heavy bleeding will occurs.

Table 1.1 Survey of Uterine Fibroid affected people over World Wide

Age	Percentage
Below 30	20%
30-35	60%
35-40	50%
Above 40	80%

Table 1.1 explains the survey of uterine fibroid diseases affected people over the world wide. This survey explains how many peoples are affected by this type of diseases based on their age.

Ultrasound focused for therapy	60%
Surgical method	52%
Personal preference for treatment	32%
Discussed with doctor and get suggestion for treatment	35%
Waiting for treatment	32%
Take surgery within 1 year	43%
With diagnosing	2.3%
Without diagnosing	18.3%

TABLE 1.2 OVERALL SURVEY OF UTERINE FIBROID

Table 2.2 explains the overall survey of uterine fibroid diseases affected people over the world wide. This survey explains how many percentage of peoples are affected by this type of diseases based on treatment method.

1.2 ULTRASOUND IMAGING

In the recent years, ultrasonic imaging found to be an appropriate tool for diagnosis of uterus related disorders.

1.2.1 ULTRASOUND

Ultrasound technology is the application of high-frequency sound waves to produce diagnostic images. These images can be used in both a diagnostic and therapeutic manner. Sound waves emitted from high-frequency probes or transducers into the patient's body are either reflected back into the probe or attenuated by the body. The sound wave that is remitted into is then converted into an electrical signal. The strength of that signal corresponds to the brightness on the monitor. Doppler studies use the same ultrasound application to display motion in an audio (continuous wave Doppler), visual (color Doppler) or graphical (pulsed wave Doppler) form. This is useful in the study of arteries and veins to detect blood flow (hemodynamics). Ultrasound technology is a safe and painless way to see the different tissues of the body. A small microphone-like device called a transducer sends and receives sound waves that are stored in the machine. Sound waves are used to display the distances and intensities of the echoes to form a two-dimensional image.

1.2.2 ULTRASOUND IMAGING TECHNOLOGY Ultrasound imaging is otherwise called as sonography or ultrasound scanning. It uses high-frequency sound waves to view soft tissues such as muscles and internal organs. Because ultrasound images are captured in real-time, they can show movement of the body's internal organs as well as blood flowing through blood vessels. In an ultrasound exam, a hand-held transducer is placed against the skin. The transducer sends out high frequency sound waves that reflect off of body structures. The returning sound waves, or echoes, are displayed as an image

on a monitor. The image is based on the frequency and strength (amplitude) of the sound signal and the time it takes to return from the patient to the transducer.

Ultrasound imaging has been used for over 20 years and has an excellent safety record. It is non-ionizing radiation, so it does not have the same risks as x-rays or other types of ionizing radiation. Even though there are no known risks of ultrasound imaging, it can produce effects on the body. When ultrasound enters the body, it heats the tissues slightly. In some cases, it can also produce small pockets of gas in body fluids or tissues (cavitation). The long-term effects of tissue heating and cavitation are not known.

1.2.3 Conversion of ultrasound to image

The creation of an image from sound is done in three steps
 Producing a sound wave
 Receiving the echoes
 Forming the image

PRODUCING A SOUND WAVE

An ultra sound wave is typically produced by a piezoelectric transducer encased in a plastic housing. Strong, short electrical pulses from the ultrasound machine drive the transducer at the desired frequency. The frequencies can be anywhere between 1 and 18 MHz Older technology transducers focused their beam with physical lenses. Newer technology transducers use phased array techniques to enable the ultrasound machine to change the direction and depth of focus. The sound is focused either by the shape of the transducer, a lens in front of the transducer, or a complex set of control pulses from the ultrasound scanner (Beam forming). This focusing produces an arc-shaped sound wave from the face of the transducer. The wave travels into the body and comes into focus at a desired depth. Materials on the face of the transducer enable the sound to be transmitted efficiently into the body (often a rubbery coating, a form of impedance matching). In addition, a water-based gel is placed between the patient's skin and the probe.

The sound wave is partially reflected from the layers between different tissues or scattered from smaller structures. Specifically, sound is reflected anywhere there are acoustic impedance changes in the body: e.g. blood cells in blood plasma, small structures in organs, etc. Some of the reflections return to the transducer.

RECEIVING THE ECHOES

The return of the sound wave to the transducer results in the same process that it took to send the sound wave, except in reverse. The return sound wave vibrates the transducer; the transducer turns the vibrations into electrical pulses that travel to the ultrasonic scanner where they are processed and transformed into a digital image.

FORMING THE IMAGE

To make an image, the ultrasound scanner must determine two things from each received echo:
 How long it took the echo to be received from when the sound was transmitted.
 How strong the echo was.

Once the ultrasonic scanner determines these two things, it can locate which pixel in the image to light up and to what intensity. Transforming the received signal into a digital image may be explained by using a blank spreadsheet as an analogy. First picture

a long, flat transducer at the top of the sheet. Send pulses down the 'columns' of the spreadsheet (A, B, C, etc.). Listen at

each column for any return echoes. When an echo is heard, note how long it took for the echo to return. The longer the wait, deeper the row (1, 2, 3, etc.). The strength of the echo determines the brightness setting for that cell (white for a strong echo, black for a weak echo, and varying shades of grey for everything in between.) When all the echoes are recorded on the sheet, we have a gray scale images

**CHAPTER 2
 PROPOSED METHODOLOGY**

This chapter deals to find out the exact view of fibroids present in the ultrasound images of uterus without noise.

3.1 BLOCK DIAGRAM OF PROPOSED WORK

In this project detection of spinach leaves disease is done using pre-processing, segmentation, morphological operation, feature extraction and classifier. Figure 3.1 shows the proposed block diagram of this project First the image is captured after that pre-processing is done to improve the intensity of image, then the required region is being generated using initial active location and is being segmented using Active Contour Location. A special feature like Histogram Oriented Gradient (HOG) is used for feature extraction. Artificial Neural Network is used as the classifier to classify the image as disease or non-disease.

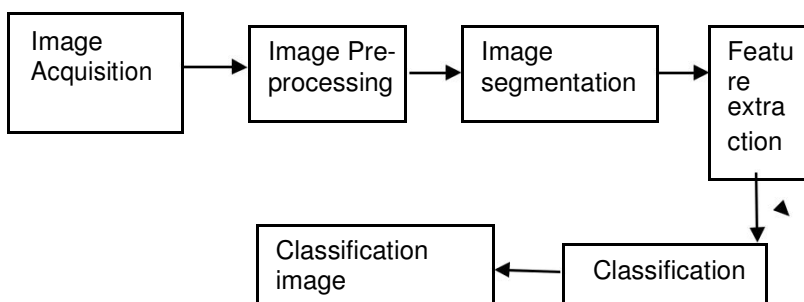


Figure 3.1 Block diagram of proposed methodology

3.2 TECHNIQUES USED IN PROPOSED WORK

The techniques used in the proposed work are,

1. Image Acquisition
2. Pre-processing
3. Image segmentation
4. Feature extraction
5. Classification

3.2.1 IMAGE ACQUISITION

The images of the Spinach leaf are captured through the camera. This image is in RGB (Red, Green and Blue) form. The captured images are in digital form.

3.2.2 IMAGE PRE-PROCESSING

Pre-processing is the crucial step of image processing applications. It is needed to enhance the image by removing the noise and adjusting the contrast in it. The image is pre-processed in order to enhance it for segmentation. Pre-processing is generally carried out in all image processing applications especially before segmentation. Contrast enhancement is carried out to make the input image clearer than normally appear. Here

contrast enhancement is done by using histogram equalisation which stretches out the intensity range.

To remove noise in image or other object removal, different pre-processing techniques is considered. Image smoothing is done using the smoothing filter. Image enhancement is carried out for increasing the contrast.

The RGB images into the grey images using colour conversion using equation

$$f(x)=0.2989*R + 0.5870*G + 0.114*B \text{ ----- (1)}$$

Then the histogram equalization which distributes the intensities of the images is applied on the image to enhance the spinach disease images.

3.2.2.1 CONTRAST ENHANCEMENT

Histogram equalization is performed here to improve the contrast of disease image which stretch out the intensity range.

This method usually increases the global contrast of many images, especially when the usable data of the image is represented by close contrast values. Through this adjustment, the intensities can be better distributed on the histogram. This allows for areas of lower local contrast to gain a higher contrast. Histogram equalisation accomplishes this by effectively spreading out the most frequent intensity values. The method is useful in images with backgrounds and foregrounds that are both bright or both dark. A key advantage of the method is that it is a fairly straightforward technique and an invertible operator. If the Histogram equalisation function is known, then the original histogram can be recovered. The calculation is not computationally intensive.

Histogram Equalization technique is used for adjusting image intensities

$$(3.1)$$

Where, P denotes the normalized histogram of 'f' with a bin for possible intensity.

The histogram equalized image g will be defined by

$$g(i) = \frac{L-1}{255} \sum_{j=0}^{i-1} P(j) \text{ (3.2)}$$

Where,

floor () rounds down to the nearest integer

f= image represented as a mr by mc matrix of integer

Consider the given image as 'x' and let ni be the number of occurrences of grey level 'i'. The probability of an occurrence of a pixel level 'i' in the image is given by equation (4.1),

$$P(i) = \frac{n_i}{n} ; 0 \leq i < L \text{ (3.3)}$$

Where 'L' is the total number of grey levels in the image; 'n' be the total number of pixels in the image. Now the cumulative distribution function corresponding to P(i) is given as in equation(3.4).

$$C(i) = \sum_{j=0}^i P(j) \text{ (3.4)}$$

Then calculate the general histogram equalization formula to equalise the intensity values by using equation (3.5).

$$h(i) = \text{round}\left(\frac{255 * C(i)}{L * C(L)}\right) \text{ (3.5)}$$

Where $cdf(v)$ be the cumulative distribution function; cdf_{min} is the minimum non-zero value of the cumulative distribution function; $M \times N$ gives the image's number of pixels and L is the number of grey levels used. Thus the image gets enhanced.

3.2.3 IMAGE SEGMENTATION

Image segmentation is the process of partitioning an image into meaningful regions or objects. Images are divided into two types on the basis of color, i.e. gray scale and color images. To differentiate different objects in the image, the image is divided into foreground and background by segmentation, whereas foreground of image is related to region of interest, and background is the rest of image. In this proposed work Active contour segmentation is used.

3.2.3.1 ACTIVE CONTOUR SEGMENTATION

Active contour model, also called Snakes . Active Contour

is a curve defined in an image which is allowed to change its location and shape until it best satisfies the predefined conditions. It segments an object by allowing the curve to settle in an object boundary. The predefined condition is the minimization of energy. It is also called as snake. It can also segment an image into foreground and background. The movement of snake is the energy minimization process. There are two types of energy which involves the external energy and internal energy. The external energy is defined to move the model toward object boundary. The energy controls the curve from moving to understand region. Mask is a binary image that specifies the initial stage of the active contour. The boundaries of the regions (white) in mask define the initial contour position used for contour evolution to segment the image. To obtain faster and more accurate segmentation results, specify an initial contour position that is close to the desired object boundaries. Active Contour is defined by $V(s)=[x(s),y(s)]$ where $s \in [0,1]$ Snake algorithm is applied

$E_{snake} = \int_0^1 (C(s) + \lambda |V'(s)|^2) ds$
 E_{int} =internal energy due to bending. Serves to impose piece wise smoothness constraint.

E_{img} =image forces pushing the snake toward image features(edges).

E_{con} =External constraints are responsible for putting the snake near the desired local minimum.

ACTIVE CONTOUR IMAGE SEGMENTATION

Fig 3.2 shows the flow chart of active contour segmentation technique first the snake algorithm for range the image segmentation. Then apply the input range of image and the snake initialization technique is applied. then the next technique is apply the Floyd & Steinberg filter in this method is filtering the original image and then calculating the energy of the snake method ,then determining a new position for each contour point of the image and it minimize the difference constraints then arrangement the contour in the arrangement process arrange the contour of the image and the arrangement process is completed next processing method is if the contour is maximum number of iteration is reach or no snake change its position in this condition

is not satisfied in this process is repeated to the energy calculation steps. Finally find the range of the image result.

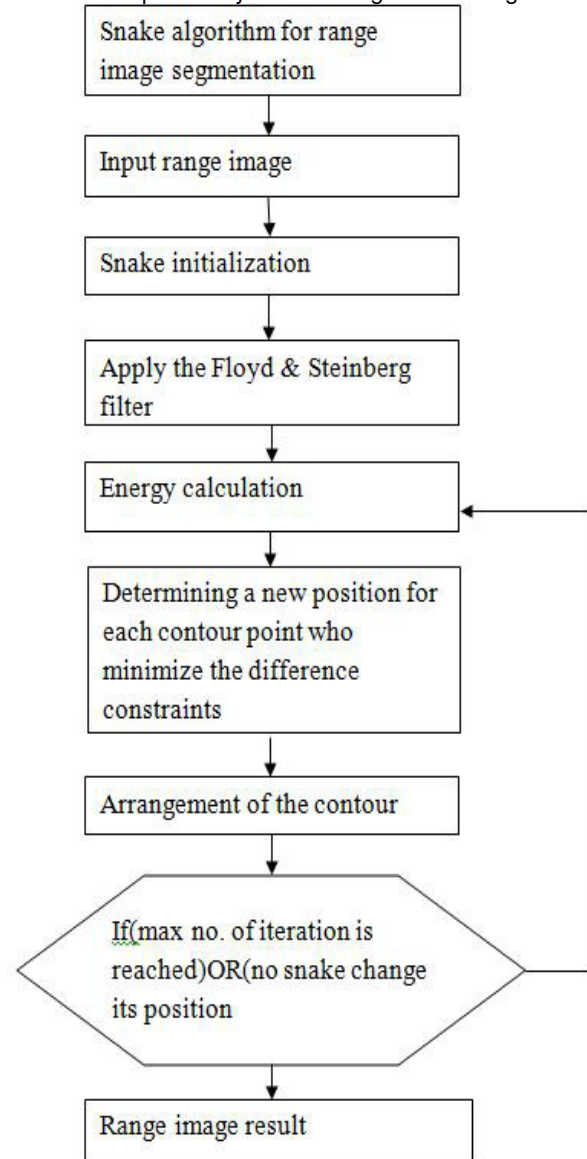


Figure 3.2 Flow chart active contour segmentation

3.2.4 FEATURE EXTRACTION

In the feature extraction method is used in the histogram of oriented gradients (HOG). The histogram of oriented gradients (HOG) is a feature descriptor used in computer vision and image processing for the purpose of object detection. The technique counts occurrences of gradient orientation in localized portions of an image. This method is similar to that of edge orientation histograms, scale-invariant feature transform descriptors, and shape contexts, but differs in that it is computed on a dense grid of uniformly spaced cells and uses overlapping local contrast normalization for improved accuracy.

3.2.5 CLASSIFICATION

Exact place of the fibroids present in the ultrasound images of the uterus are clearly detected and extracted. Finally, the exact portion of fibroids present in the ultrasound images of uterus are extracted.

IV. CONCLUSION

The presence of noise and low contrast in medical images make it difficult to perform visual inspections and computed aided analysis of the images. In this paper, the fibroids are extracted from the Ultrasound images are done by two different techniques. In the first method the removal of speckle noise from the Ultrasound images using SRAD filter has been discussed. High resolution contrast enhancement is another main requirement for the clear detection of the fibroids, for which I have selected CLAHE technique. This method is not suitable for all images especially low contrast images, and the accuracy of detection was very low. Because the low contrast images, locating the centroid point is very difficult. So the regions of exact area of cyst/fibroids in those images are very difficult. In which we got the accuracy of detection as 82%. The second method is based on the FCM clustering. Here the contrasts of the input images are improved by the logarithmic transform. And the image is segmented into number of clusters by the use of FCM clustering followed by the morphological operations are used. The extracted cystic/fibroidic area is compared with the affected area present on the original image by using active contour based segmentation. Here this experiment is conducted on the different test images which yield 97% accuracy.

REFERENCES

1. Ammara Masood, Adel Ali Al-Jumaily (2013), "Fuzzy C Mean Thresholding based level set for Automated segmentation of Skin Lesions", Journal of Signal and Information Processing, Vol. 4, pp. 66-71.
2. Anthony Krivanek and Milan Sonka (1998), "Ovarian Ultrasound Image Analysis: Follicle Segmentation", IEEE transactions on medical imaging, vol. 17no 6, pp 935-944.
3. Anita Khanna, Meenakshi Sood, and Swapna Devi (2012), "US Image Segmentation Based on Expectation Maximization and Gabor Filter", International Journal of Modeling and Optimization, Vol. 2, No. 3.
4. Ashika Raj (2013), "Ovarian Follicle Detection for Polycystic Ovary Syndrome using Fuzzy C-Means clustering", International Journal of Computer Trends and Technology (IJCTT).
5. B.Potocnik, D.Zazula, D. Korze, (1997), "Automated computer assisted detection of follicles in ultrasound images of ovary", J.Med.Sys.21 (6) 445-457.
6. B.Potocnik, B.Viher, D.Zazula,(1998), "Computer Assisted detection of ovarian follicles based on ultrasound images", Verzprem, Hungary, pp 24-34.
7. B.PotocnikD.Zazula,(2002), "Automated Analysis of sequence of ovarian ultrasound images Part I: segmentation of single 2d images", Image Vision and Computing, vol 20, no 3, pp 217-225.
8. Chunfei Zhang, Zhiyi Fang (2013), "An Improved K-means Clustering Algorithm", Journal of Information & Computational Science 10: 1, pp- 193-199.
9. Divya Sindhu and Surender Singh (2014), "Image Segmentation in Various Domains using Two Phase Clustering Approach", International Journal of Emerging Trends & Technology in Computer Science (IJETTCS) Volume 3, Issue 4, ISSN 2278-6856.
10. Dr. G. Padmavathi, Mr. M. Muthukumar and Mr. Suresh Kumar Thakur (2010), "Nonlinear image segmentation using Fuzzy C Means Clustering Method with thresholding for underwater images", IJCSI International Journal of Computer Science Issues, Vol. 7, Issue 3, No 9, pp. ISSN (Online): 1694-0784, ISSN (Print): 1694-0814.
11. Ehsan Nadernejad, Mohammad Reza Karami, Sara Sharifzadeh, Mostafa Heidari (2009), "Despeckle Filtering in Medical Ultrasound Imaging", Contemporary Engineering Sciences, Vol. 2, no. 1, 17.
12. Ghousia Usman, Usman Ahmad and Mudassar (2013), "Improved K-Means Clustering Algorithm by Getting Initial Centroids", Ahmad World Applied Sciences Journal 27 (4): 543-551, ISSN 1818-4952.
13. G.T. Shrivakshan, Dr. C. Chandra sekar (2012), "A Comparison of various Edge Detection Techniques used in Image Processing", IJCSI International Journal of Computer Science Issues, Vol. 9, Issue 5, No 1 ISSN 1694-0814.
14. Harvey Rhody (2005), "Basic Morphological Image Processing", Lecture notes
15. H.Chidiac, D.Ziou,(1999), "Classification of Image Edges", Vision Interface'99, Troise-Rivieres, Canada, pp. 17-24.
16. M.Woodhall, C.Linquist,(1997), "New Edge Detection Algorithms Based on Adaptive Estimation Filters", Conference Record of the 31st Asilomar IEEE Conference on Signals Systems & Computers, volume: 2, pp. 1695-1699.
17. M.A.Gore, P.L.Nayudu, V.Vlaisavljevic, N.Thomus (1995), "Prediction of ovarian cycle outcome by follicular characteristics".Stage1", Human Reproduction, vol 10, pp 2313-2319.
18. Madhu Yedla, Srinivasa Rao Pathakota and T M Srinivasa (2010), "Enhancing K-means Clustering Algorithm with Improved Initial Center", International Journal of Computer Science and Information Technologies (IJCSIT), Vol. 1 (2), pp- 121-125.
19. Madhuri Gedam, Hetal Amrutia and Nabnita Mandal (2013), "Biomedical Ultrasound Image Enhancement

using SRAD”, International Conference & workshop on
Advanced Computing, ISSN: 2249-0868.

